

Interventional Radiologists Offer Minimally Invasive Approaches to Venous Diseases

John Moriarty, MD, FSIR
Associate Clinical Professor of Medicine and Radiology
Director of Cardiology-Interventional Radiology Innovation
Department of Radiology
David Geffen School of Medicine at UCLA



Venous disease comprises a group of circulatory disorders that are both very common and highly treatable, including deep vein thrombosis, pulmonary embolism and varicose veins. Using advanced image guidance, interventional radiologists are able to offer highly successful, minimally invasive treatment for these conditions that in most cases enables patients to quickly return to enjoying their normal activities.

Deep Vein Thrombosis

“Deep vein thrombosis is not only very common, with up to one million new cases each year in this country, but also carries a large burden of disease,” says John Moriarty, MD, FSIR, associate professor of radiology and medicine (cardiology). Blood clots, which typically form in veins in the legs, can cause pain and swelling. When clots persist over time, the condition is known as post-thrombotic syndrome and can cause heavy, swollen legs with pain, discoloration and skin ulcers.

Interventional radiologists can remove clots directly from patients’ veins and place stents to restore blocked blood flow. Using a combination of imaging techniques for visualization, physicians insert a catheter just above the ankle and work up through the leg, breaking up and suctioning out clots.

Pulmonary Embolism

Clots in the veins can also break free and travel to the heart and lungs, where they increase pressure in the pulmonary arteries and damage the right side of the heart, presenting a significant risk of sudden death. Treating pulmonary embolism is frequently an emergency procedure.

Following a prompt and careful evaluation, a multidisciplinary treatment team tailors a treatment plan to the individual patient. Procedures are performed with X-ray, ultrasound and — increasingly — cardiac ultrasound and CT guidance as a series of catheters are passed through the veins and into the heart and

lungs. Often, a small ultrasound transducer is placed within the heart to guide the way through the heart to where clots are located.

IVC Filters

IVC filters are small metal cages that can be placed in the interior vena cava to trap clots before they can travel through the heart and become pulmonary emboli. The filters are retrievable and should remain in the body only as long as they are needed — usually a matter of weeks. “The longer IVC filters are left in patients, the higher the complication rate,” warns Dr. Moriarty. “I’m frequently asked by patients about filters that they’ve been told cannot be removed. This is almost always incorrect. Almost all filters can be removed if they get sent to a dedicated center like ours.” Using advanced imaging and removal techniques that include the use of lasers, UCLA interventional radiologists have successfully removed IVC filters that have been in place for decades, those that have moved in the body, and filters that have broken apart.


Varicose Veins

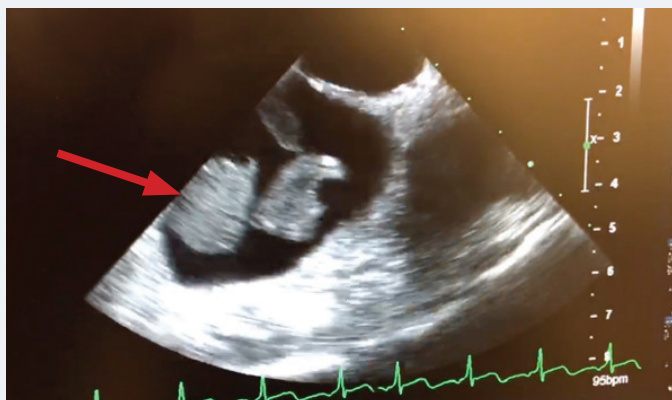
Varicose veins are a common condition in the superficial veins of the legs, where they cause pain, leg heaviness and itching and present a cosmetic problem. Varicose veins result when the valves that control the flow of blood in veins become dysfunctional and allow blood to reflux, or flow backward. This disturbance to the normal flow of blood causes the veins to dilate.

The same dysfunction can affect veins in other parts of the body, including the pelvic area. In men, a varicocele in the veins going into the testicles can cause pain and infertility. In women, pelvic congestion syndrome can cause severe pelvic pain.

Interventional radiologists can treat varicose veins in an office procedure that takes about an hour. A catheter is placed into the vein under image guidance and radiofrequency energy is used to ablate the inside of the vein and cut it off from the flow of blood.

Care for Venous Diseases at UCLA

UCLA interventional radiologists maintain dedicated venous clinics in Westwood, Santa Monica and Manhattan Beach. Each clinic is equipped with the imaging technology to treat all non-emergency venous problems. In addition, emergency treatment for DVT and pulmonary embolism is available at UCLA hospitals both in Westwood and Santa Monica. 



Ultrasound shows large clots in the right side of the heart, at risk for moving to the lungs and causing a Pulmonary Embolus (PE)