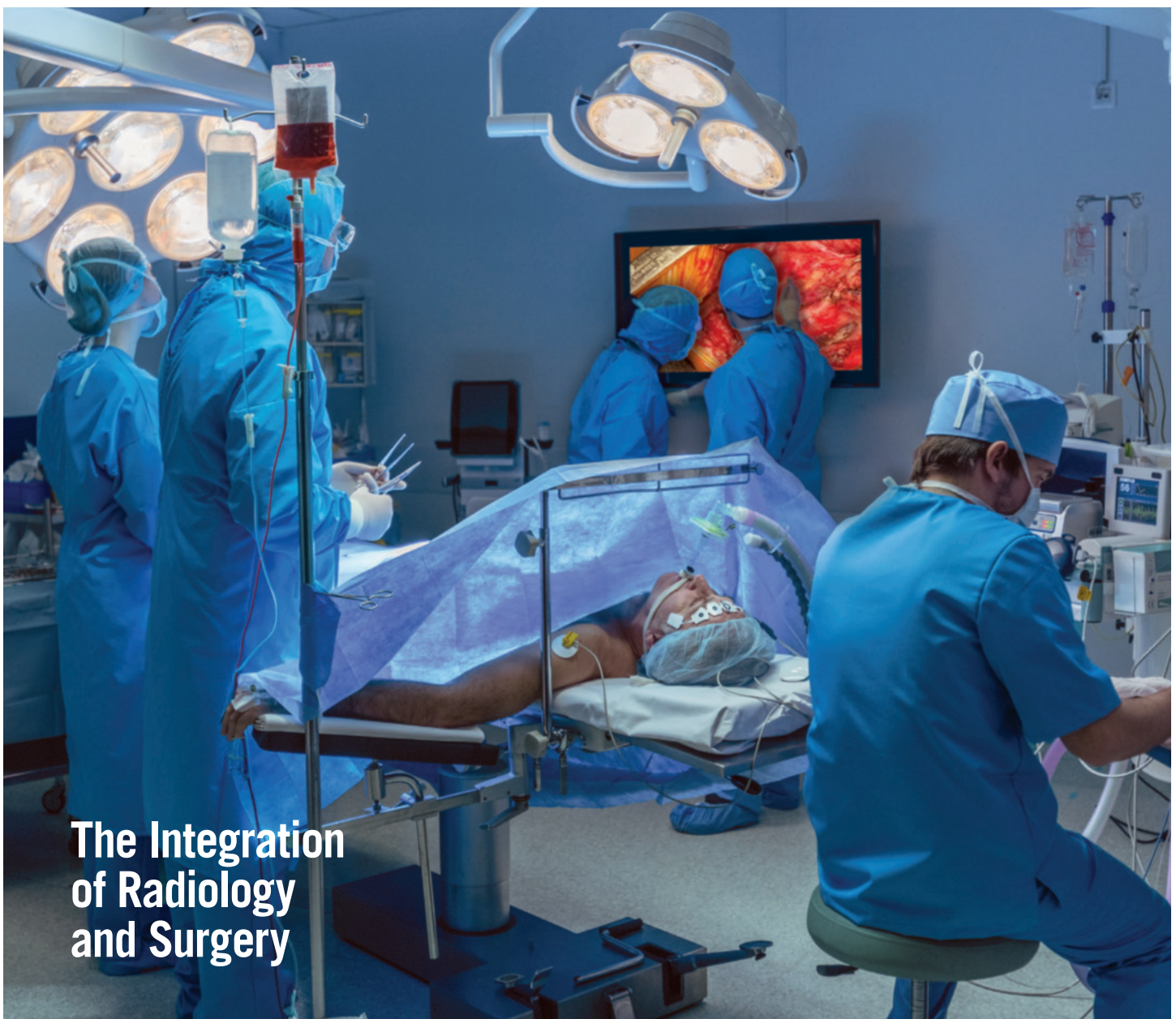

UCLA Radiology

NEWSLETTER OF THE DEPARTMENT OF RADIOLOGICAL SCIENCES

SPRING 2020



The Integration of Radiology and Surgery

IN THIS ISSUE | CHAIR'S MESSAGE [P. 2](#) | ADVANCED IMAGING & BRAIN TUMOR CARE [P. 3](#) |
MRgFUS ABLATION FOR ESSENTIAL TREMOR [P. 4](#) | COLLABORATIVE CARE FOR CONGENITAL HEART DISEASE [P. 5](#) |
DIAGNOSIS AND INTERVENTION IN LIVER DISEASE [P. 6](#) | DEPARTMENT HIGHLIGHTS [P. 7](#)

Chair's Message




Dieter Enzmann, MD

Distinguished Professor of Radiology
Leo G. Rigler Chair
Executive Medical Director, UCLA Health
Department of Radiological Sciences
David Geffen School of Medicine at UCLA

Normally this editorial reflects features in this newsletter, but the appearance of the COVID-19 pandemic necessitated a last minute change. Radiology's central clinical role, while clear to us, has become more evident to others, including patients. We are more front-line with daily patient contacts (about 1500/day) than is generally recognized. Our excellent diagnostic services offer ill patients continued access, and our IR services provide needed treatment, all while taking COVID-19 precautions into consideration. The Department, being well organized, has mounted rapid, appropriate responses as a team of faculty, trainees, professional staff, and administrative staff. Radiology being deeply steeped in technology, both in knowledge and infrastructure, has used these distinct advantages to enable multiple forms of adapting on a person-person level, as well as "working at a distance."

Distributed workflows, long a feature of PACS, allow us to work at safe physical distances, including from home. Our IR culture of primacy of patient care has served us extremely well by providing essential treatments while scaling down procedures that could be safely delayed. Our Department has responded appropriately, aggressively, and with aplomb in balancing the safety of our healthcare teams with our patient's needs, which while having been prioritized differently, nevertheless do remain.

Some perspectives on change are interesting. While one may view the COVID-19 crisis as a wave washing over us, that thinking suggests that once it recedes we will return to the pre-COVID 19 world. That is unlikely. Even when the term "new normal" is used the underlying assumption often is that this is somewhat temporary, and we will subsequently return back to the real "normal." As I noted in an article entitled "The Nature of Change"

(JACR, May 5, 2014), complex systems exhibit an interesting stepwise pattern of change termed "punctuated equilibrium." That stepped pattern features long periods of equilibrium (the horizontal portion of a step) that are interrupted by abrupt shorter periods of rapid change, the punctuation (the vertical portion of a step). The vertical height represents the proportional amount of change in the system. Once the vertical step has formed, it ends at a new, "horizontal" portion, i.e., the "new normal." The vertical step consists of a concatenation and superimposition of numerous sigmoid-shaped diffusion of innovation curves concentrated in time. The incorporation of AI into radiology was already forming an on-going punctuation. COVID-19 is a sudden, new "high-octane" curve, which when added to the ongoing punctuation, will result in an even bigger ultimate punctuation changing radiology forever, and probably even more rapidly than anticipated. 

Highly Advanced Imaging Contributes to World Class Brain Tumor Care

Benjamin M. Ellingson, PhD

Professor of Radiology and Psychiatry
Director, UCLA Brain Tumor Imaging Laboratory (BTIL)
Department of Radiological Sciences
David Geffen School of Medicine at UCLA



For some types of brain tumor — particularly high-grade malignancies like glioblastoma — treatment decisions must be made quickly due to the aggressive nature of the disease. Choosing to begin, continue or change treatments are decisions best made with timely input from a variety of specialists. At UCLA, an integrated, interdisciplinary team works together to produce the best possible treatment outcomes.

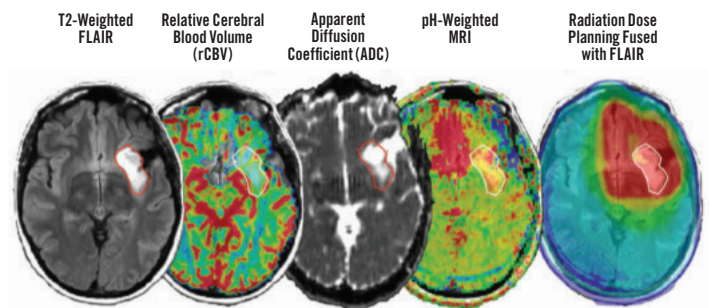
“When treating most types of cancer, you can surgically remove various aspects of the tumor to see how the treatment has affected the tumor tissue,” explains Benjamin M. Ellingson, PhD, professor of radiology and psychiatry and director of the UCLA Brain Tumor Imaging Laboratory. “With brain tumors, we rely heavily on imaging to provide information on whether a particular treatment is working.”

At UCLA, radiologists and imaging scientists participate at every stage of brain cancer patients’ care. Beginning with initial entry into the system — including Emergency Department visits when patients present with acute symptoms — UCLA radiologists and scientists help manage patients through diagnosis and staging, presurgical and radiation oncology target planning, postsurgical assessment and therapeutic response to radiation, and routine follow-up imaging for all treatment modalities.

UCLA has developed a number of new imaging modalities in the course of researching and treating brain tumors. Leading-edge imaging technologies being used at UCLA to help our interdisciplinary team make better-informed treatment recommendations include pH-weighted MRI and oxygen-enhanced MRI.

Both of these imaging technologies exploit the unusual metabolism that some brain tumors exhibit in favoring glycolysis for energy production. The pH-weighted MRI technique detects the concentration of lactic acid, a byproduct of glycolytic metabolism. UCLA radiologists are able to quantify the lactic acid buildup to track response to a variety of brain cancer treatments. “different genetic or molecular subtypes of tumors have different metabolic signatures,” states Dr. Ellingson. “We can pick up these patterns with a short, seven-minute scan. It’s very clinically feasible and has been integrated into UCLA’s standard of care for appropriate patients.”

Oxygen-enhanced MRI can distinguish between normal tissue, which uses oxygen to create energy, and some types of malignancies that use anaerobic glycolysis whether oxygen is available or not. Images made while the patient breathes different concentrations of oxygen distinguish tissue metabolizing glucose with oxygen from tissue relying solely on anaerobic glycolysis. “Some types of malignancies will use only anaerobic glycolysis. Others, such as slow-growing IDH mutant tumors, prefer oxidative phosphorylation,” explains Dr. Ellingson.




Advanced brain imaging available at UCLA (first four images from left), combine metabolic and physiologic information to inform treatment decisions, including radiation treatment strategy (right image).

Other highly advanced imaging technologies available at UCLA include 18F-FDOPA PET, which uses an amino acid imaging tracer, and 18F Clofarabine PET, which can be used to monitor immunotherapies. Another imaging technology that UCLA is bringing online is sodium MRI. It will be used to examine brain tumor electrophysiology as well as other biological processes.

In addition to offering these and other highly advanced imaging techniques available at few, if any, other centers, UCLA Radiology has more widely implemented the advanced imaging techniques that may be available, but are not yet routine, at other academic centers. Imaging modalities like perfusion and diffusion MRI are offered at a number of centers, but at UCLA they are integrated into routine follow-up care throughout our clinical enterprise.

“With these technologies, we’re able to look at vascularity within a tumor — angiogenesis and blood volume — and track whether they are changing over time as tumors grow or respond to therapy,” states Dr. Ellingson.

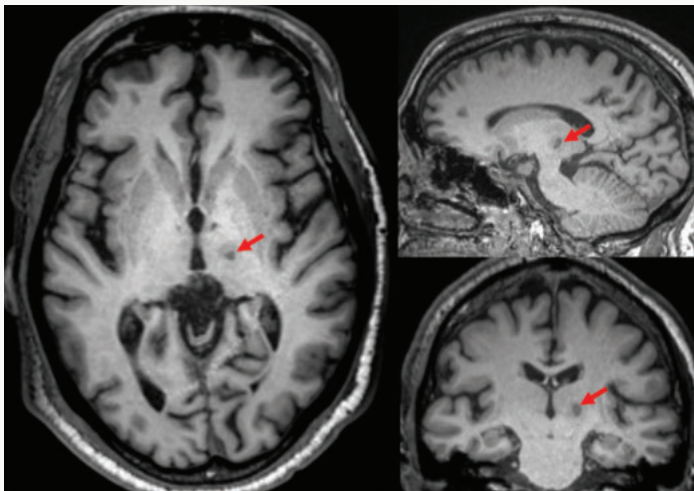
Finally, UCLA Radiology has spearheaded an international movement to have a standardized core MRI imaging protocol for brain tumors. All UCLA brain tumor patients get the same anatomical imaging protocol at all time-points throughout their care independent of where within the UCLA system they are seen. This same type of standardized imaging has since been mandated by the National Cancer Institute and Food and Drug Administration for all clinical trials, with many leading academic institutions adopting UCLA’s existing standards. This will prove important in brain cancer research, where standardized imaging will allow relatively modest numbers of patients at each institution to be combined into larger, more meaningful clinical trials. 

Team Approach Improves Targeting of Focused Ultrasound Treatment for Essential Tremor

Noriko Salamon, MD, PhD
Professor of Radiology
Vice Chair of Academic Affairs
Chief of Neuroradiology
Department of Radiological Sciences
David Geffen School of Medicine at UCLA



Pharmacotherapies have shown only limited success in the treatment of essential tremor, and while deep-brain stimulation of the ventral lateral nucleus of the thalamus has been available for decades, many patients still do not receive adequate care for the condition, significantly affecting their quality of life. MRI-guided focused ultrasound (MRgFUS) is now also being used to treat essential tremor with unilateral thalamic ablation. Whereas earlier ultrasound equipment required a craniotomy to create a window for the acoustic waves, modern ultrasound transducers and techniques eliminate the need to open the skull, allowing for a noninvasive procedure that can be used in treating essential tremor.



T1 axial, coronal and sagittal imaging after the MRg FUS. Red arrow shows ablation area in the left Vim nucleus. The patient's symptom significantly improved during the MRgFUS.

Computed tomography (CT) is used to assess the skull thickness, with CT data being registered with magnetic resonance (MR) images to allow proper targeting through the skull. Real-time MR imaging and thermometry improve target accuracy as ultrasound energy is concentrated at the target location from an ultrasound helmet with a multielement hemispheric phased array transducer. The procedure ablates the target tissue, creating a lesion at the site while sparing adjacent tissue.

Results of a clinical study comparing MRgFUS thalamic ablation to a sham procedure indicated that the ablation procedure improved tremor symptoms (expressed on a scale of 0 to 32 using the Clinical Rating Scale for Tremor) by an average of 47 percent at three months. This compares to an improvement of just 0.1 percent for the sham procedure.

Anatomical Targeting


Precise targeting is a key to achieving optimal clinical outcomes. “The target is a very tiny structure,” notes Noriko Salamon, MD, PhD, professor of radiology and neuroradiology at the David Geffen School of Medicine at UCLA. “When precision is not perfect, outcomes will vary among patients.”

Targeting thalamic ablation is sometimes done based solely on a series of measurements from the center of the thalamus. Because the size of the thalamus is relatively consistent from person to person, and the sizes and locations of its internal components also vary only slightly, this system produces a moderately accurate treatment target. This has led some to believe that the procedure can be performed without information on the individual’s specific anatomy provided by a neuroradiologist. “Measurements usually get you close, but I think we do better having an anatomical specialist — the neuroradiologist — contribute to targeting. Subtle technical differences can make a big difference in outcomes,” states Dr. Salamon.

One technique that UCLA neuroradiologists use to more precisely locate the ventral lateral nucleus and assess its connectivity is diffusion tensor imaging. Because structures deep in the brain are connected to the superficial cortex by a series of white matter fibers, the fibers can be traced from the cortex to their corresponding deep-brain structures.

“Fiber tractography is a 3D reconstruction technique used to assess white-matter tracts using diffusion tensor imaging data,” explains Dr. Salamon. “It reveals the fiber connections allowing me to avoid motor fibers and pick up the exact tract responsible for the tremor.”

Integrated, Interdisciplinary Care

The integrated interdisciplinary approach to neurological disorders at UCLA ensures these crucial collaborations take place. But interdisciplinary collaboration isn’t just a byproduct of UCLA’s clinical structure, it’s woven into the institutional fabric. “Experts from many areas come together and exchange ideas before making a decision,” states Dr. Salamon. “That’s part of the culture at UCLA, which is not easy to accomplish.” Dr. Salamon believes that these collaborations have been important in making her a better, more effective clinician. Working in isolation, she can extract from an image what is meaningful to her, but her regular exchanges with physicians in other specialties have taught her to recognize what in an image will be most meaningful to them as well. 

Close Collaborations Advance Congenital Heart Disease Care

J. Paul Finn, MD
Professor of Radiology
Vice Chair of Innovative Technology
Chief of Diagnostic Cardiovascular Imaging
Department of Radiological Sciences
David Geffen School of Medicine at UCLA



UCLA offers comprehensive care to pediatric and adult congenital heart disease (CHD) patients, but that level of care would not be possible without a web of interdisciplinary collaborations that make clinical expertise in a range of specialties available to each CHD patient. “Congenital heart disease requires a focused effort on the part of caregivers in every clinical area,” explains J. Paul Finn, MD, professor of radiology and chief of Diagnostic Cardiothoracic Imaging at UCLA. “Embracing clinical integration in all our treatment pathways is very important.”

The first-line imaging study for congenital heart disease patients at UCLA is usually an echocardiogram, which is performed by a cardiologist. Because of the complexity and wide variation in anatomy among congenital heart disease patients, these are highly specialized echocardiologists who see only congenital heart disease patients.

When advanced imaging is needed, UCLA radiologists contribute their imaging expertise. “We need to work closely with our colleagues in cardiology and cardiac surgery to know what we need to focus on and what questions we have to address through our MRI and CT studies,” states Dr. Finn. Their findings are shared at multidisciplinary clinical conferences held twice a week.

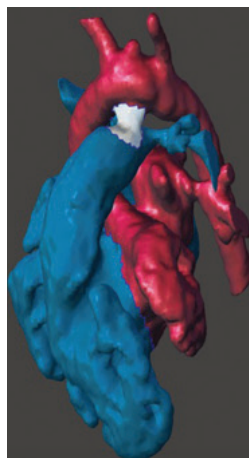
Sharing Study Results

Presenting advanced imaging studies at their clinical conferences to illustrate cases for discussion is very important to effective collaboration. UCLA radiologists make use of digital viewers that support the DICOM (Digital Imaging and Communications in Medicine) standard to more effectively share their findings. “While an imaging study report includes the essential information from the study, it sometimes doesn’t convey the full visual picture that we can communicate when we show the actual study images to the surgeons and cardiologists,” Dr. Finn explains.

Among the DICOM viewers that UCLA uses is one that was developed by a UCLA radiologist that has grown to become one of the leading DICOM viewers and image processing platforms. “We’ve followed a path of developing or inventing new ways to do MRI studies, but we have to convey the findings to our surgeons and cardiologists in a useful way and in a timeframe that has clinical relevance,” explains Dr. Finn. “For that, we had to get a bit creative about developing tools and resources.”

3D Printing and Virtual Reality Puts Imaging Data in Surgeons’ Hands

Because we are recognized as a leading center for congenital heart disease, complex cases with very abnormally developed anatomy are often referred for treatment to UCLA. Here, our pediatric cardiac surgeons (Glen Van Arsdell, MD, Hillel Laks, MD, and Reshma Biniwale, MD) may have to determine if it is possible, for example, to perform a bi-ventricular repair — so the patient will have a more normal heart anatomy with two pumping chambers — or if the repair will have to rely on a single ventricle



4D MUSIC MR image in a newborn baby is used to create a virtual model of a surgical procedure whereby a communication (white) is created between the aorta (red) and the pulmonary artery.

to perform the work of two chambers. Bi-ventricular repairs are preferred for offering better long-term outcomes and quality of life, but it can be very difficult for surgeons to determine the optimal surgical plan of such repairs — or even their feasibility — based on imaging alone.


3D printing has promise to greatly aid surgical planning by presenting a detailed physical model of the existing anatomy of these sometimes tiny hearts. But outsourcing 3D printing was proving to be time- and resource-intensive when care demanded prompt decision making.

“4D MUSIC — Multiphase Steady State Imaging with Contrast — using ferumoxytol can generate very detailed images of all the chambers and blood

vessels in the heart, even in small hearts with very rapid heart rates” states Dr. Finn. “The question is how do we quickly and effectively turn these into printed models for our surgeons.”

Gregory S. Perens, MD, professor, Division of Pediatric Cardiology, began experimenting with a relatively inexpensive 3D printer and was able to generate several very useful 3D models. Takegawa Yoshida, MD, a research associate in the Department of Radiology collaborates with Dr. Perens to convert the 4D MUSIC image data to a file format supported by the 3D printer.

This technological collaboration between cardiology and radiology to produce 3D printed models quickly and inexpensively has facilitated clinical collaborations by enabling radiologists to more effectively share anatomical data with surgeons. UCLA physicians continue to work together to further develop this technology and gain more insight into how it can be used to determine if various types of surgical reconstruction will be appropriate and successful.

Furthermore, as Virtual Reality hardware and software become increasingly available, the anatomy of the 3D beating heart can be visualized even without physical models. These tools will add a new dimension to our ability to convey relevant information for surgical planning. 

Radiologists Collaborate in Caring for Patients with Liver Disease

David Lu, MD

Professor of Radiology


Chief of Cross Sectional Interventional Radiology

Director of CT, High Intensity Focused Ultrasound

Program and UCLA Liver Tumor Ablation Program

Department of Radiological Sciences

David Geffen School of Medicine at UCLA



For patients with liver cancer and other liver disease, “it’s very important to identify information that helps determine the health of the liver, and to identify tumors and anatomic features that can affect surgical technique,” states David Lu, MD, professor of radiology and director of the UCLA Liver Tumor Ablation Program.

The multidisciplinary treatment teams at the Pflieger-UCLA Liver Cancer Center and Dumont-UCLA Liver Transplantation Program rely on experts in diagnostic liver imaging to help determine and plan treatments, as well as interventional specialists to help carry them out. UCLA was among the first centers in the U.S. to establish integrated, multidisciplinary programs for liver cancer and liver transplantation.

At UCLA, patients with hepatocellular carcinoma or metastatic liver cancer are seen in a multidisciplinary clinic, where they have access to subspecialty physicians from all relevant specialties in a single, convenient visit, including hepatobiliary surgeons, hepatologists, liver oncologists and diagnostic and interventional hepatobiliary radiologists. Patients’ treatment plans can be determined during that initial clinic visit with input from all specialists.

Re-interpreting Outside Scans

Most liver disease patients seen at UCLA and are referred from outside physicians and have had imaging studies performed at other clinics. UCLA hepatobiliary radiologists re-evaluate the available imaging to help determine the optimal treatment plan. “Identifying and staging tumors accurately in the liver is quite challenging and it’s not uncommon that lesions previously identified as cancer turn out in fact to not be cancerous at all,” states Dr. Lu. “Also, lesions that initially seemed to be suitable for liver resection or liver transplant, sometimes turn out after review

to be at more advanced stages, making alternate therapeutic plans more appropriate.”


When further imaging studies are needed, it is important that the most current scanning protocols — some of which were developed at UCLA — are followed. “Even if a facility has the most current CT and MRI equipment, if they’re not being put to use with the most optimized scanning methods, the images are not going to produce the right results,” states Dr. Lu. Many tumors can be accurately identified and staged only with carefully coordinated timing between the delivery of contrast and the imaging scans. Strict scanning protocols at UCLA help ensure optimal scan quality.

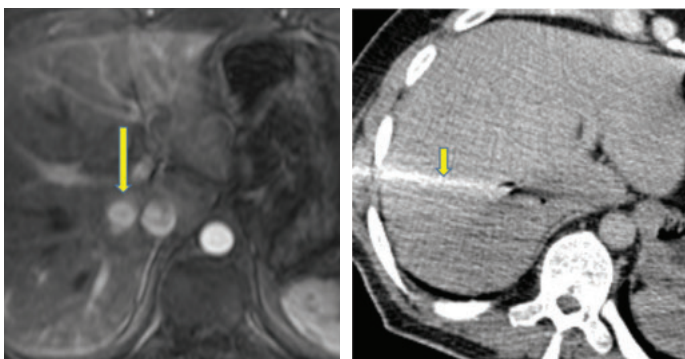
Interventional Oncology Treatments as a Bridge to Transplantation

Patients with liver cancer awaiting a donor organ for transplantation — a wait that is likely to be at least several months if not multiple years — are at risk for developing tumor growth that will reduce the effectiveness of liver transplant, and therefore jeopardize their status on the waiting list. At UCLA, these tumors are treated by interventional radiologists using minimally invasive thermal ablation or embolization techniques, and patients are carefully monitored for new tumor growth with continued treatment as necessary. In this manner, patient’s transplantation plans are kept on track. UCLA recently produced data showing that the integration of tumor ablation followed by transplantation produces very high 10-year survival rates in patients with early stage liver cancer.

Intraoperative Ultrasound and Ablation

In a unique interdisciplinary collaboration at UCLA, radiologists are joining surgeons in the operative room during surgery for liver cancer. After having mapped out the locations of lesions with preoperative imaging studies, radiologists use intraoperative ultrasound to locate the mapped lesions. “Many of these are deep lesions that cannot be seen superficially or felt with palpation,” explains Dr. Lu. In addition to locating the lesions, the intraoperative ultrasound enables radiologists to help surgeons determine the best way to safely resect deep lesions based on anatomic features of the patient’s liver.

In some instances, lesions deep in the liver cannot be safely resected. In these cases, the radiologist is able to use intraoperative ultrasound-guided ablation to destroy the lesions while minimizing the damage to surrounding tissue. 



Patient with history of renal cell carcinoma referred to the Liver Cancer Center for definitive management of a reported single hypervascular metastasis to the liver (long arrow, on arterial phase MRI). On review of imaging the lesion diagnosis was changed to most likely focal nodular hyperplasia, a benign condition. Subsequent biopsy was performed by a hepatobiliary interventional oncologist (short arrow show biopsy needle under CT), and the benign diagnosis was confirmed. Patient ended up not needing any invasive treatment or chemotherapy.

Opening of UCLA Radiology's Breast Imaging Center



The UCLA Santa Monica Integrated Breast Care Center celebrated the opening of UCLA Radiology's latest Breast Imaging Center within its walls. The milestone was celebrated in-style on January 23, 2020, at a spectacular Open House in the award-winning glass-front medical building located at 1223 16th Street. "With the opening of our new Breast Imaging Center, we are now able to provide necessary pre-operative wire localization procedures for patients in the same building, only steps away from the operating room," said Anne C. Hoyt, M.D., Medical Director and Section Chief of UCLA Breast Imaging.

The center, open since 2012, is well-known for its one visit program where patients with newly diagnosed breast cancer are seen in a single visit by a team composed of clinicians specializing in radiology, oncology, breast surgery, pathology, radiation

oncology, plastic surgery, genetics and social support. During the visit, a personalized treatment plan is developed for each woman and appropriate appointments are scheduled for her by the team's nurse navigator. "Gone are the days when our patients with wires in place were transported down the sidewalk from our 15th street Women's Imaging Center to the 16th Street operating room. We are all under one roof now," said Hoyt.

For more information on the UCLA Santa Monica Integrated Breast Care Center's breast imaging services, visit uclahealth.org/radiology/smbreastcare.

For patients with newly diagnosed breast cancer, appointments can be made at the UCLA Santa Monica Integrated Breast Care Center by calling (424) 259-8791.

Q3D Lab Team

Our team of image analysts in the Q3D lab use software to generate interactive 3D visualizations and measurements of anatomy, giving interventionalists and surgeons at UCLA unparalleled ability to plan effective and efficient procedures for the best possible patient outcomes. We are dedicated to quality, rapid turnaround time, and delivering results that improve decision making for patients and their physicians. Our mission is to generate advanced quantitative imaging reports and 3D visualizations, and deliver them when and where needed for decision-making and patient care. We use the latest image analysis tools and translate new techniques into a high quality, high throughput clinical service.



From left: Brenda Brown, Operations Manager; Matt Brown, Director; Varun Badheka, Lead Analyst; Fei Ye, Image Analyst; Cesar Arellano, Image Analyst; Missing from photo: Emma Stackpole, Image Analyst; Kalyani Vyapari, Image Analyst; Danny Gomez, Image Analyst

UCLA Health

Department of Radiological Sciences

405 Hilgard Avenue
Los Angeles, CA 90095

NONPROFIT
ORGANIZATION
U.S. POSTAGE

PAID

UCLA



You have the power to make a world of difference in radiological sciences. Join forces with UCLA to advance human health and improve outcomes and quality of life for patients and their loved ones. If you would like information on how you can help, please contact:

Gemma Badini
Senior Director of Development, UCLA Health Sciences
310-206-9235
GBadini@mednet.ucla.edu
or go to: www.uclahealth.org/radiology/giving

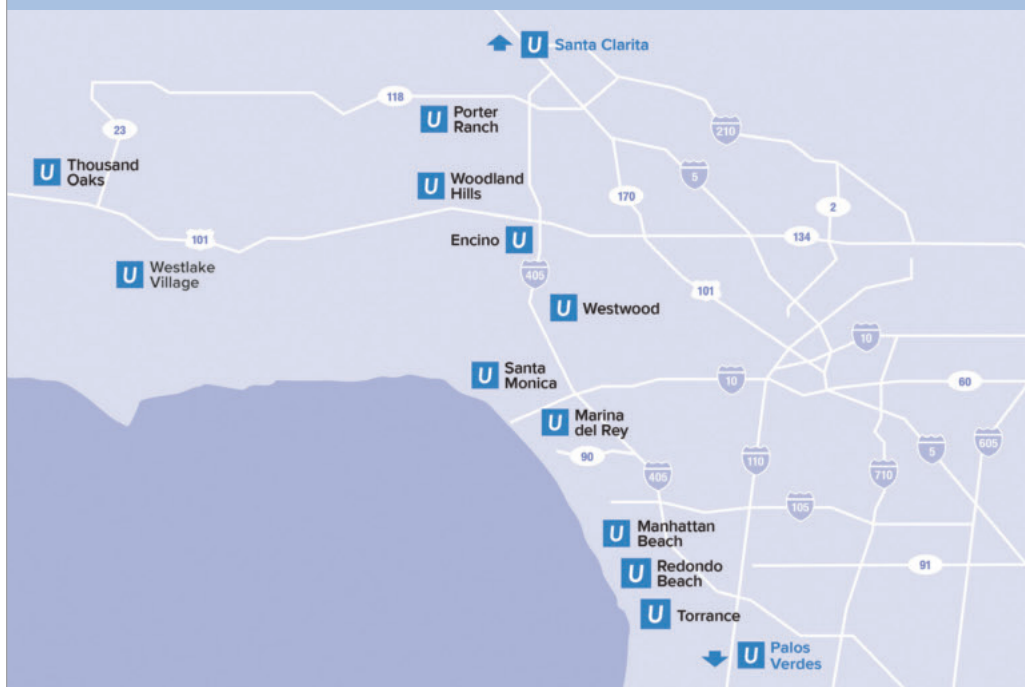

UCLA Health's hospitals in Westwood and Santa Monica placed #1 in California and #6 in the nation in the 2019-2020 *U.S. News & World Report* survey.

Our locations

UCLA Radiology is committed to providing outstanding patient care through excellence in clinical imaging at a number of convenient locations.

For more information, visit www.uclahealth.org/radiology or call (310) 301-6800.



UCLA Radiology

SPRING 2020

LEO G. RIGLER CHAIR AND PROFESSOR
Dieter R. Enzmann, MD

EXECUTIVE VICE CHAIR
Jonathan G. Goldin, MD, PhD

EXECUTIVE CLINICAL DIRECTOR
Brenda Izzi, RN, MBA

CHIEF ADMINISTRATIVE OFFICER
Suzie Morrel, MSF

BUSINESS DEVELOPMENT
Leila Farzami

WRITER
David Barrad

DESIGN
SD Graphics



Contact us at:
RadNewsletter@mednet.ucla.edu

A Publication of
UCLA Department of Radiological Sciences
©2020 UCLA Radiology Department All rights reserved